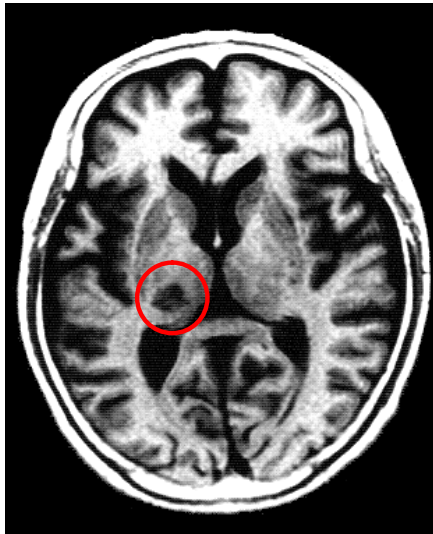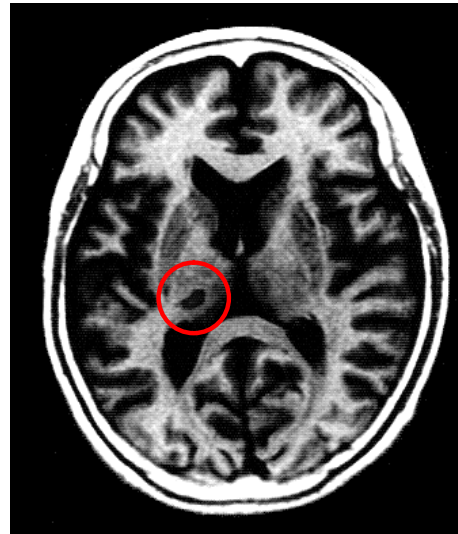


# MRI Scan of Stroke Patient

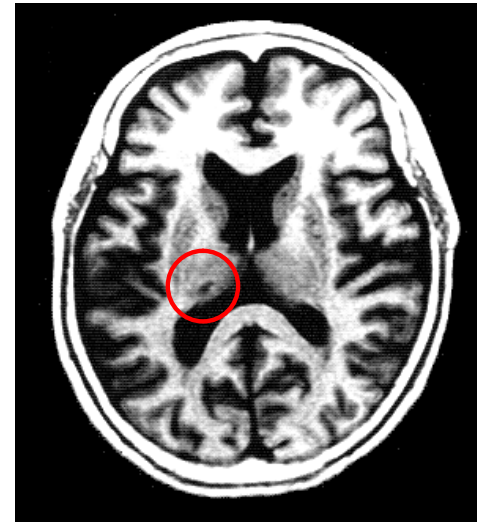### MRI Scan of Stroke Patient (Case 1)



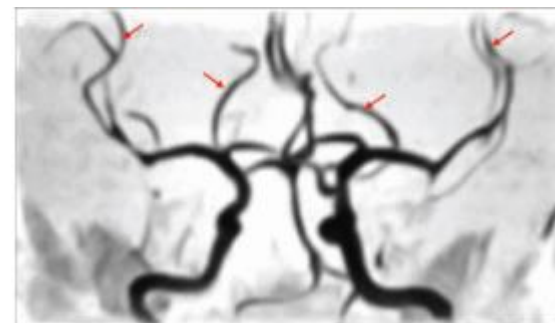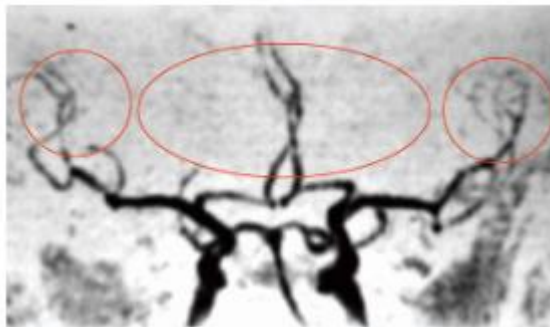
Before Treatment



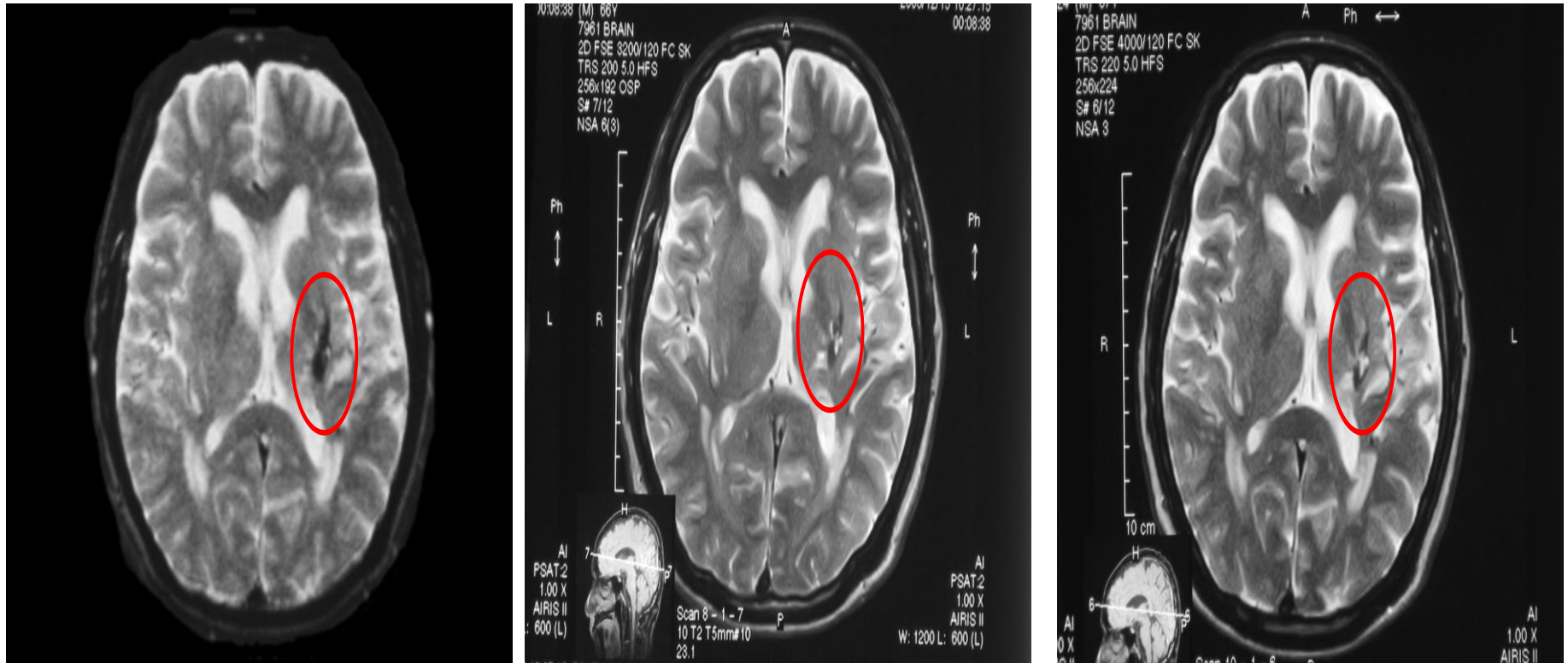
2 month



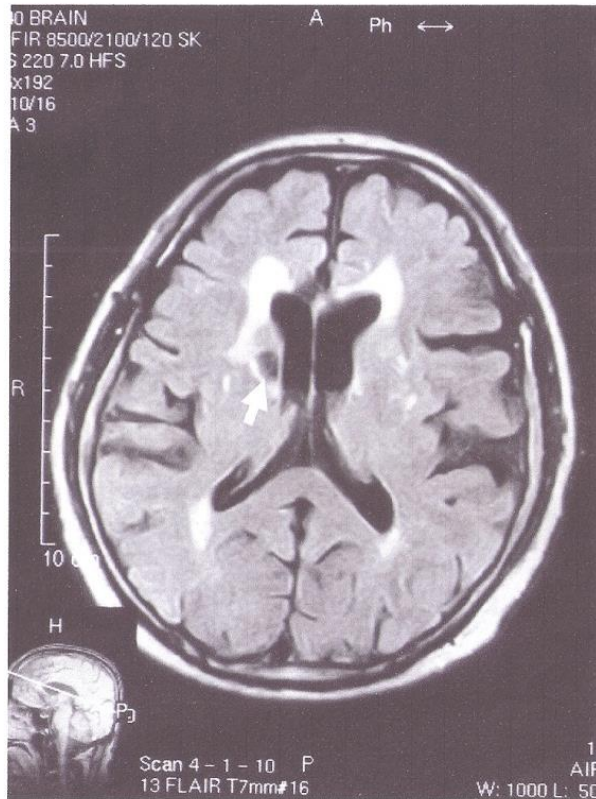
4 month



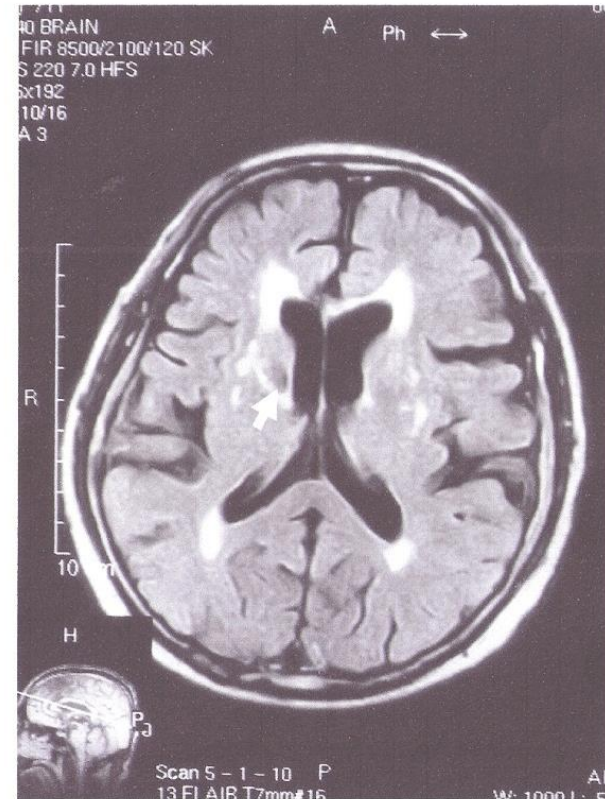
## MRI Scan of Stroke Patient (Case 2)



### MRI Scan of Stroke Patient (Case 3)



還元電子治療前  
(矢印は病巣を示す)

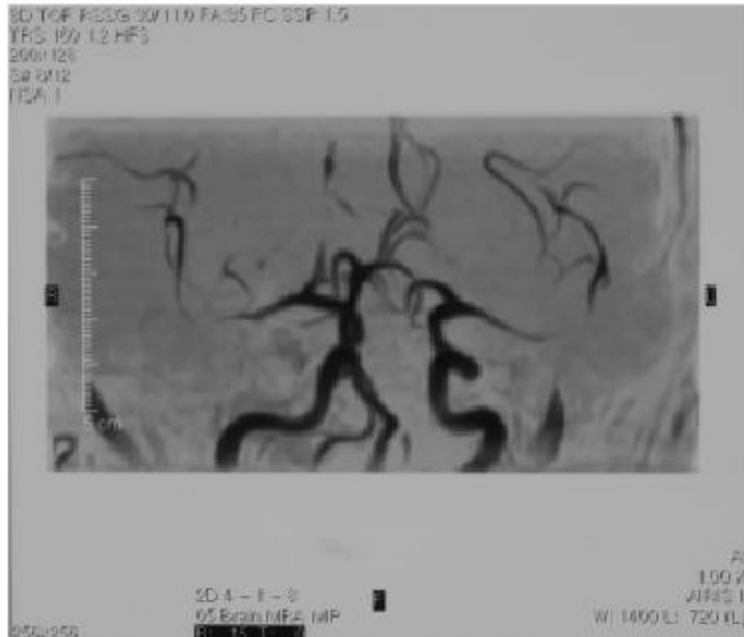


還元電子治療8ヵ月後  
(矢印は病巣を示す)

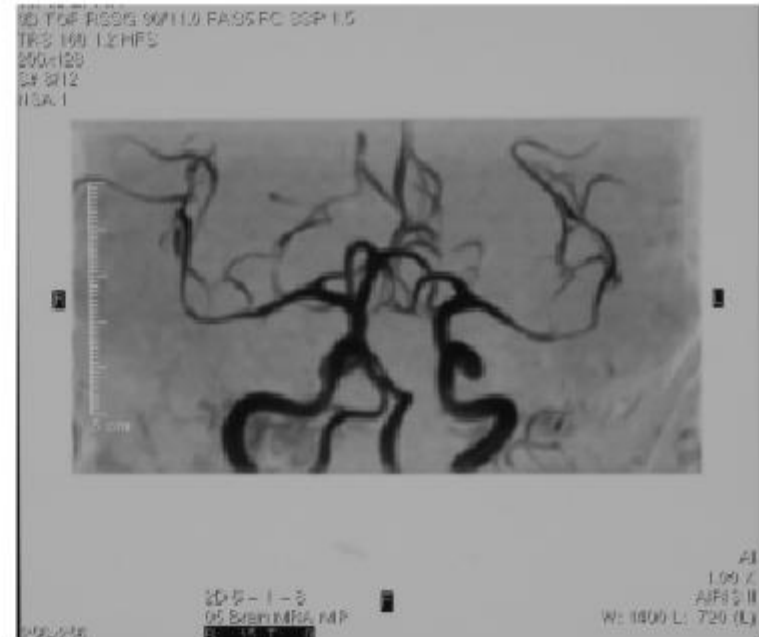# **Cerebral Arteriosclerosis** (69 year old, male)

## Cerebral Arteriosclerosis (69 year old, male)

### MR Angiography



The 26th shooting February 19, 2007



The 19th shooting September 19, 2007

Electron reduction of blood flow improvement after treatment (7 months), arterial brain